

# Treatment of maxillary transversal deficiency by using a mini-implant-borne rapid maxillary expander and aligners in combination

**Benedict Wilmes,<sup>a</sup> Nour Tarraf,<sup>b</sup> and Dieter Drescher<sup>a</sup>**  
*Duesseldorf, Germany, and Sydney, Australia*

Bone-borne rapid maxillary expansion distraction devices are used to achieve a more skeletal expansion and to avoid dental side effects of conventional expanders such as tipping of anchorage teeth. In this article, we report the use of a prefabricated expander fixed on 2 mini-implants in the anterior palate. This allows for the insertion of the mini-implants and the expander to occur without the need for an impression or any laboratory procedures. Especially when aligners are going to be used, the use of a mini-implant-borne expander seems to be reasonable because the expander can be left in place as a skeletal retainer during the aligner finishing. (*Am J Orthod Dentofacial Orthop* 2021; ■: ■-■)

**M**axillary transverse deficiency is a common orthodontic problem, and it is often associated with a unilateral or bilateral posterior cross-bite. Rapid maxillary expansion (RME) is considered the optimal procedure to achieve a skeletal widening of the maxilla.<sup>1,2</sup> Because the forces are usually transmitted to the skeletal structures via the anchor teeth, distribution of the forces to as many teeth as possible and completion of root growth are considered essential. However, besides the therapeutically intended skeletal expansion, side effects such as tipping of the teeth, root resorption, decrease in buccal bone thickness or dehiscence, and loss of marginal bone height resulting in gingival recessions may occur.<sup>3-6</sup>

To reduce the unwanted side effects of tooth-borne maxillary expansion, several maxillary expansion appliances have recently been introduced, which share the load between the anchorage teeth and 2-4 mini-implants. Wilmes et al<sup>7</sup> have introduced the hybrid hyrax

expander in 2007 using 2 mini-implants in the anterior palate and 2 (deciduous) molars.<sup>8-10</sup> Similar hybrid expanders were published in the following years by Garib et al<sup>11</sup> in 2008, Lee et al<sup>12</sup> in 2010, and Moon et al<sup>13</sup> in 2015, called the mini-implant assisted rapid palatal expansion. The T-Zone in the anterior palate provides a safe insertion area for the mini-implants away from tooth roots and blood vessels while providing the best quality cortical bone.<sup>14-16</sup> Many studies have shown the advantages of mini-implant assisted rapid palatal expansion compared with tooth-borne expanders inducing less tipping of anchorage teeth, a more skeletal expansion,<sup>17,18</sup> less decrease of the buccal bone thicknesses of anchorage teeth,<sup>19</sup> a significantly higher nasal airway flow<sup>20</sup> and less root resorption of anchorage teeth.<sup>21</sup> A disadvantage of skeletal borne expanders is the need for local analgesia and the insertion of mini-implants. However, there seems to be no difference between pain intensity and discomfort during RME treatment with a conventional hyrax appliance vs a mini-implant anchored appliance.<sup>22</sup>

The conventional procedure for the use of the hybrid hyrax is first to insert mini-implants, take an impression, or scan, manufacture the appliance in a laboratory and then insert it in a subsequent appointment. To avoid this 2-step procedure, a prefabricated expander borne on 2 mini-implants was designed, which can be inserted in the same appointment immediately after mini-implant placement. This expander is prefabricated in 3 different sizes (on the basis of the distance of the

<sup>a</sup>Department of Orthodontics, University of Duesseldorf, Duesseldorf, Germany.

<sup>b</sup>Private practice, Sydney, Australia, and Discipline of Orthodontics, Faculty of Dentistry, University of Sydney, Sydney, Australia.

All authors have completed and submitted the ICMJE Form for Disclosure of Potential Conflicts of Interest, and none were reported.

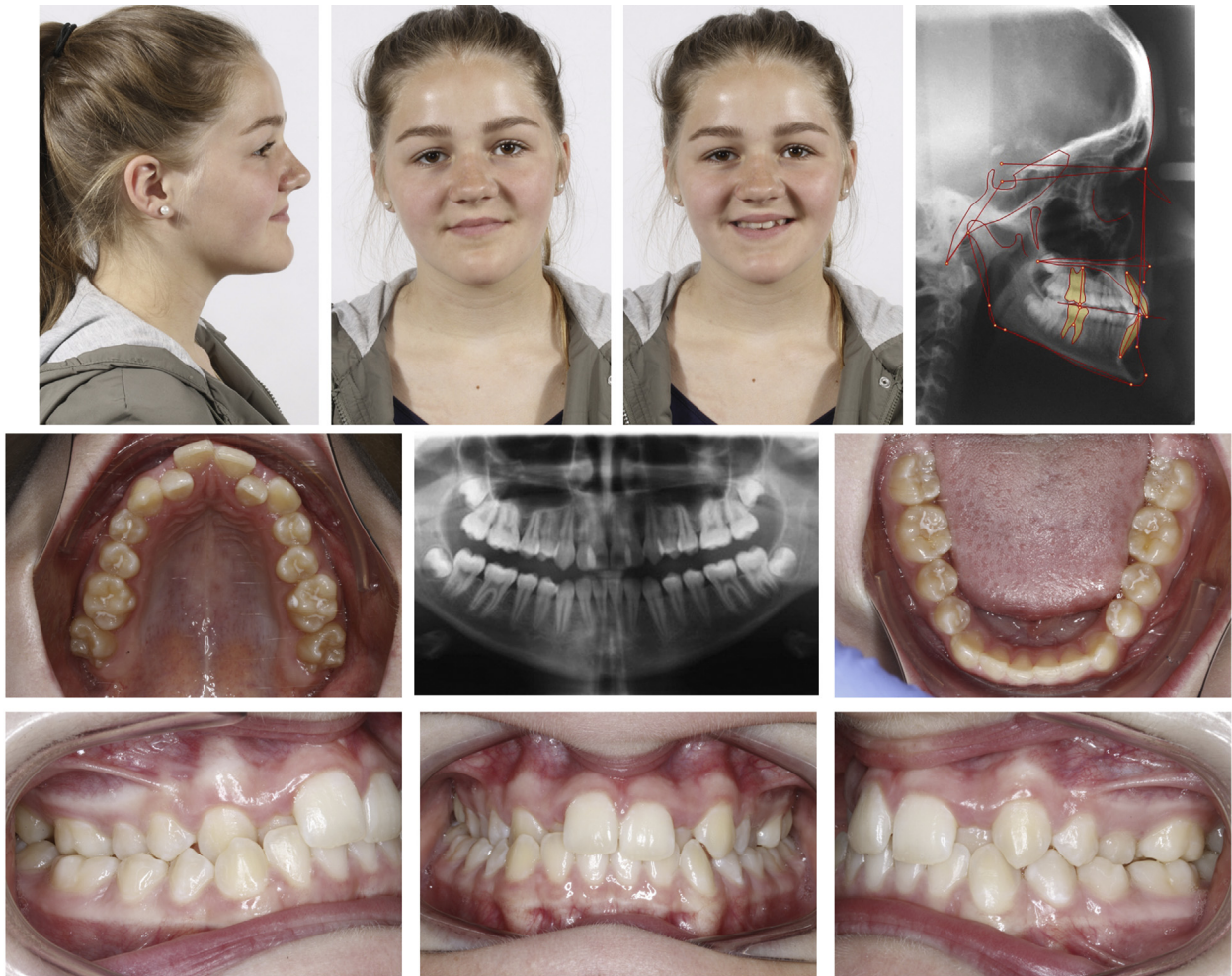Address correspondence to: Benedict Wilmes, Department for Orthodontics, University of Düsseldorf, Moorenstr. 5, D-40225 Düsseldorf, Germany; e-mail, [Wilmes@med.uni-dueseldorf.de](mailto:Wilmes@med.uni-dueseldorf.de).

Submitted, August 2020; revised and accepted, November 2020.

0889-5406/\$36.00

© 2021 by the American Association of Orthodontists. All rights reserved.

<https://doi.org/10.1016/j.ajodo.2020.11.037>



**Fig 1.** A 13-year-old female patient with a severe maxillary transversal deficiency.

mini-implant centers: 6, 8, 10 mm) and can be adapted directly chairside. After insertion of 2 mini-implants in optimal insertion sites in the anterior palate (T-Zone), the appropriate expander size is chosen and additionally adapted to the distance of the 2 mini-implants by pre-turning of the expansion screw. The expander can be activated over a distance of 10 mm, which means even if the maximum pre-turning distance of 2 mm is done, 8 mm are still available for maxillary expansion.

An increasing number of orthodontic patients present seeking invisible or esthetic orthodontic treatment with clear sequential thermoplastic aligners. A treatment objective of bodily tooth movement with aligner therapy exclusively can prove challenging to achieve with a high degree of predictability.<sup>23,24</sup> This is especially true when attempting a significant amount of expansion in the maxillary arch. Houle et al<sup>25</sup> and Zhou and Guo<sup>26</sup> reported severe tipping of the teeth instead of a desired

bodily tooth movement when aligners only were used for expansion. Consequently, it seems beneficial to combine a mini-implant borne expander and aligners to treat patients with a maxillary transversal deficiency and wish for invisible treatment.

#### CASE REPORT


A 13-year-old female patient presented with a severe maxillary transversal deficiency (Fig 1). Intraoral examination showed a bilateral crossbite in the permanent dentition. The panoramic radiograph revealed the presence of all third molars. Pretreatment lateral cephalometric analysis showed a mild skeletal Class III (Wits,  $-1.2$  mm; ANB,  $0.5^\circ$ ) with a slightly prognathic mandible (SNB,  $83.2^\circ$ ; Table). The relative merits, shortcomings, and risks of each treatment modality were clearly explained to the patient and her parents. They

**Table.** Cephalometric summaries

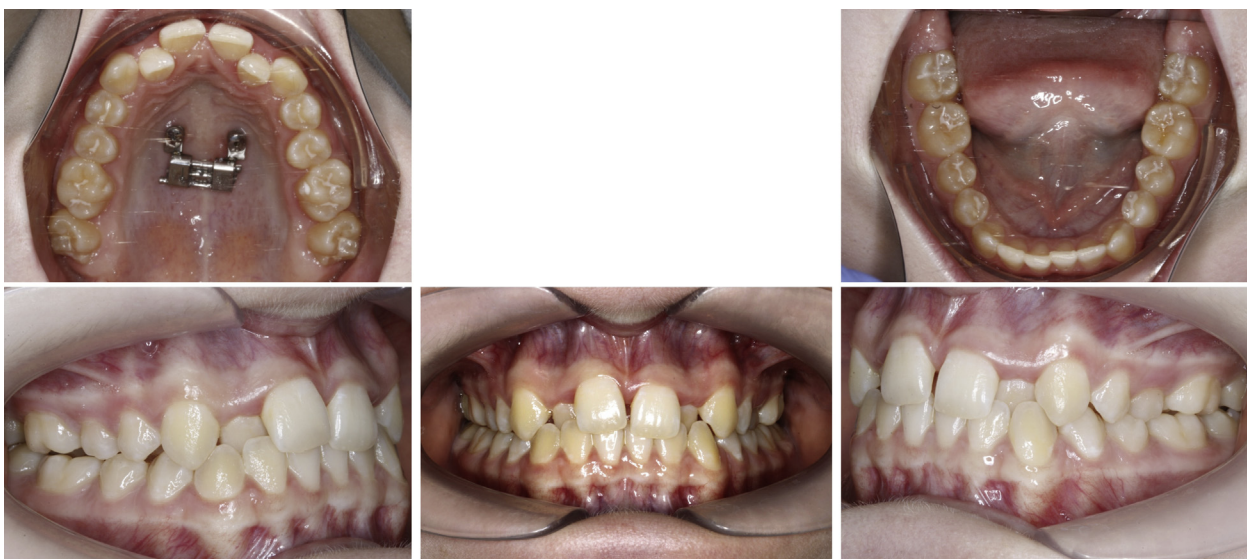Measurements	Pretreatment	Posttreatment
NSBa	122.3°	126.6°
NL-NSL	6.8°	7.8°
ML-NSL	26.9°	27.3°
ML-NL	20.1°	19.5°
SNA	83.7°	84.3°
SNB	83.2°	83.2°
ANB	0.5°	0.7°
Wits	-1.2 mm	-1.9 mm
U1-NL	115.0°	114.6°
L1-ML	88.5°	89.7°
U1-L1	136.4°	136.2°
Overjet	2.1 mm	2.8 mm
Overbite	2.0 mm	1.8 mm

made an informed decision to proceed with a treatment using a mini-implant borne expander for the maxilla and aligners for leveling of the teeth afterward.

The treatment started with the insertion of 2 mini-implants ( $2 \times 9$  mm) in the anterior palate under local anesthesia (Fig 2, A). A prefabricated expander (Fig 2, B; 8 mm, BMX expander, psm North America, Inc, La Quinta, Calif) was first adapted by pre-turning the expansion screw directly chairside and fixed with 2 fixation screws (Fig 2, C). Expansion activation was initiated by performing 1 activation per day for a total of about 0.2 mm expansion per day. After 4 weeks of activation, the maxilla was expanded by approximately 5.5 mm (Figs 3 and 4). Subsequently, scans were taken for the aligner finishing (Clear Correct, Round Rock, Tex; Fig

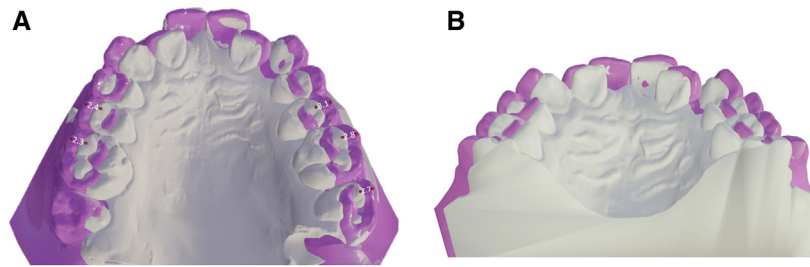


**Fig 2.** A, Insertion of 2 mini-implants ( $2 \times 9$  mm) in the anterior palate under local anesthesia. B, Prefabricated BMX expander (8 mm). The expander itself has 10 mm of activation. C, Expander fixed with 2 fixation screws.

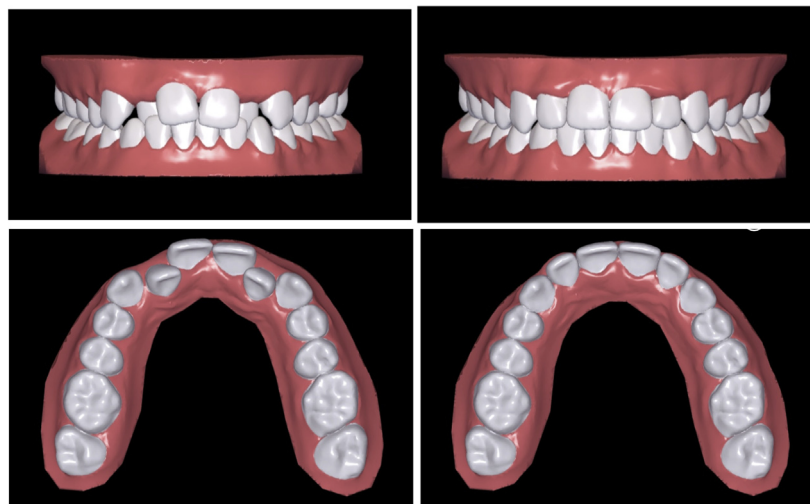


**Fig 3.** Intraoral situation after 4 weeks of expansion.

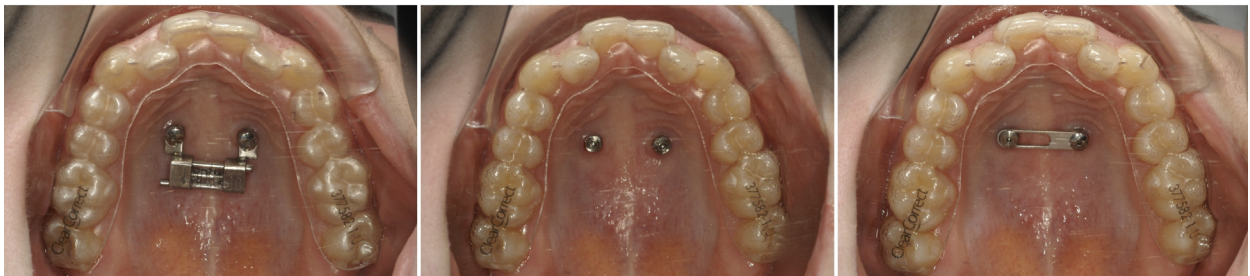



**Fig 4.** Superimposition of the before and after expansion scans by matching the area of the palatal rugae.<sup>39</sup> **A,** Measurement of the expansion distances (in mm; Blender software, version 2.8). **B,** Cross-section in the area of the mesio buccal cusps of the maxillary first molars.



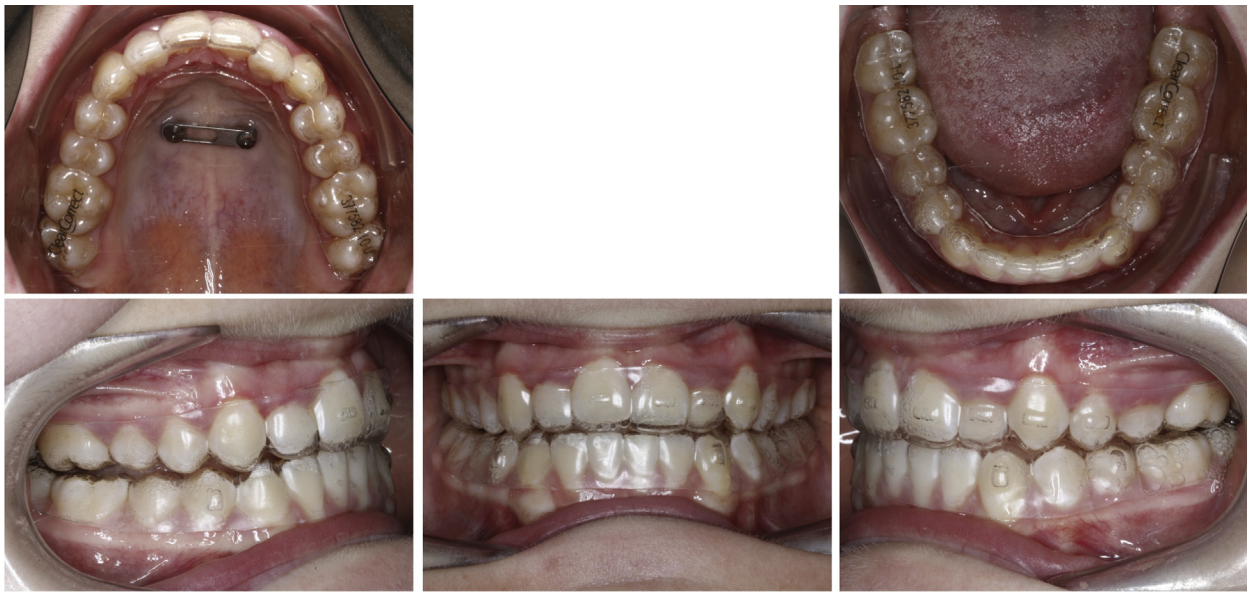**Fig 5.** Treatment planning for the aligner finishing (before and after).



**Fig 6.** Skeletal retention with the BMX expander and a miniplate.

5). The BMX expander stayed in place for skeletal retention and was substituted during the aligner finishing by a miniplate to achieve higher patient comfort (Fig 6). The aligner treatment (Fig 7) comprised 22 aligners (2-week change), including 1 refinement and was

finished after 10 months (Fig 8). The whole treatment duration was 12 months (1 month of expansion, 1 month for aligner manufacturing, and 10 months of aligner finishing). For retention, removable vacuum-formed retainers were prescribed. The occlusion improved



**Fig 7.** Aligners in situ.

because of the settling of the teeth during the retention period of 6 months (Fig 9).

## DISCUSSION

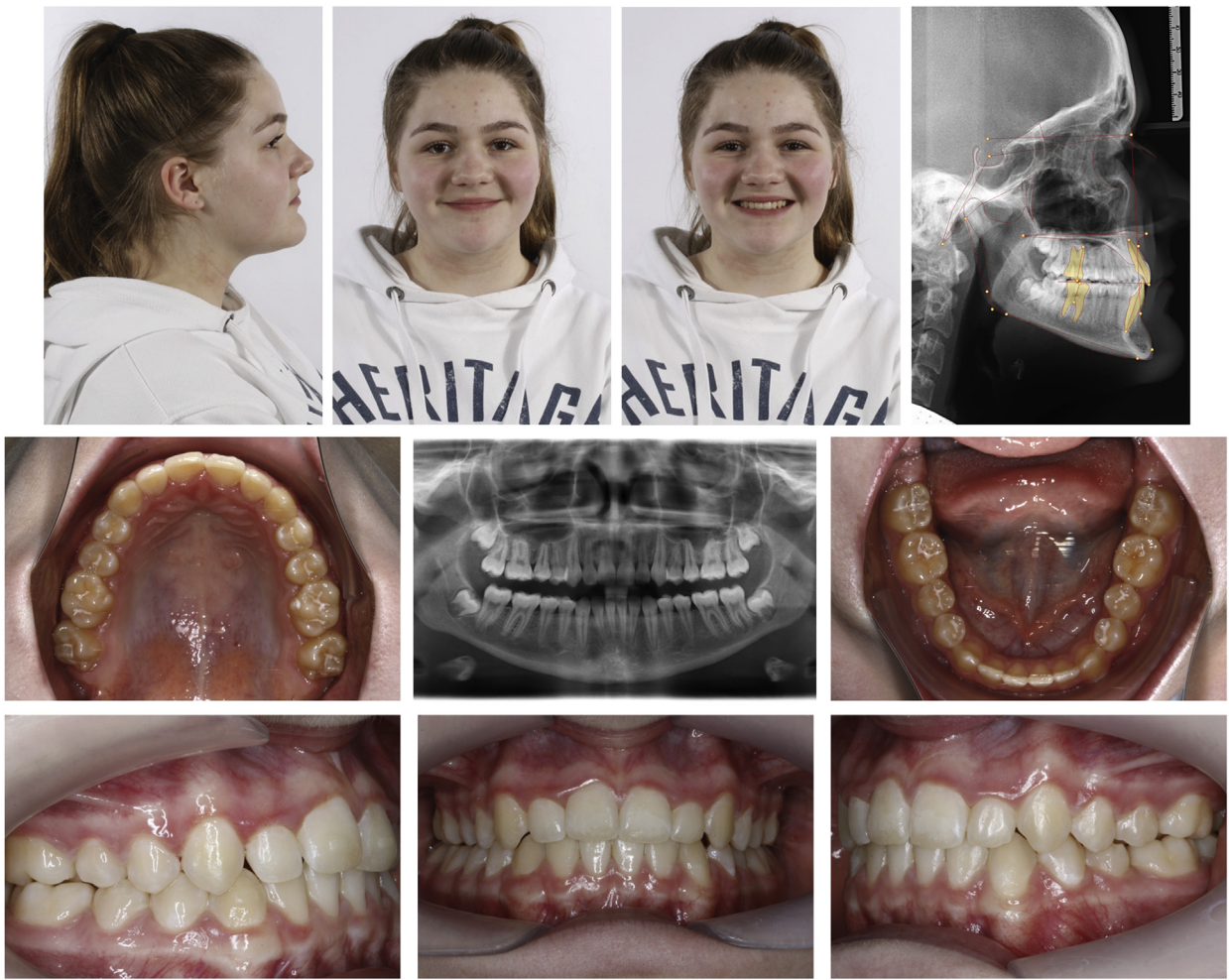Expansion of the maxilla with aligner therapy exclusively can prove challenging to achieve with a high degree of predictability because severe tipping of the teeth instead of a desired bodily tooth movement occurs when aligners are used for expansion.<sup>25,26</sup> Consequently, some clinicians prefer a 2-phase strategy: (1) tooth-borne RME plus retention period, and (2) aligner treatment. The disadvantage of this 2-phase strategy may be a long total treatment time because of the needed retention period. A second flaw may be the need for overcorrection and the risk of relapse during the aligner phase. If a mini-implant-borne expander is used, first, the aligner treatment can be started immediately after expansion, and second, the expander can be left in place for retention purposes without any interferences with the teeth to be moved. In addition, there is less risk of root resorption of anchorage teeth if the expander is mini-implant borne.<sup>21</sup> The only disadvantage of a mini-implant-borne expander is the need for insertion of mini-implants. However, there seems to be no additional pain or discomfort for the patients if mini-implants are used for an RME.<sup>22</sup> The failure rate of mini-implants in the anterior palate is reported to be 1%-5%, which is significantly lower than in other regions.<sup>27-31</sup> In the anterior palate, a superior bone

quantity and quality combined with thin attached mucosa and minimal risk of tooth-root injuries can be observed.<sup>28,29,32</sup> The ideal zone with the lowest failure rates seems to be directly posterior from the palatal rugae.<sup>14,15</sup>

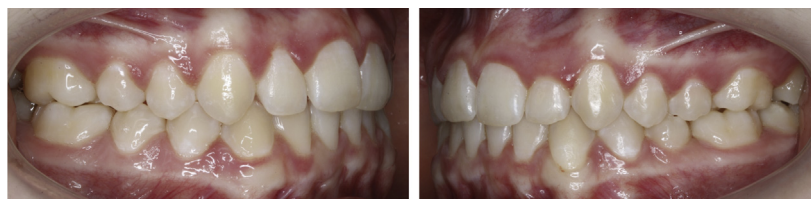The benefit of using temporary anchorage devices (TADs) in maxillary expansion has been questioned previously in the literature.<sup>33</sup> However, recently published studies and literature reviews have shown the advantages of using mini-implants for maxillary expansion in terms of more skeletal and less dental side effects such as molar tipping.<sup>17,20,34,35</sup> From our clinical experience, the mini-implant insertion site might play an important role in how TADs can benefit maxillary expansion. When TADs are inserted paramedian in the anterior palate and away from the alveolar process, they seem to have the advantage of eliminating the buccal tipping of the lateral segments and even increasing the basal expansion.<sup>36</sup>

In this patient, the daily activation rate was very slow (0.2 mm/d). If tooth-borne expanders are used, the daily activation is usually higher because dental movements are to be avoided.<sup>37</sup> If a mini-implant-borne expander is used, the expansion can be very slow because there is no risk of tooth movement. Future studies are needed to evaluate the optimal daily expansion rate. Studies are also needed to assess up to which age 2 mini-implants are sufficient for RME (present patient was aged 13 years). Carlson et al<sup>38</sup> have shown that RME can





**Fig 8.** Treatment result after a total treatment time of 12 months.



**Fig 9.** Occlusal settling in the retention phase (after 6 months).

also be achieved in some adult patients without the need for additional surgical assistance.

With the bone-borne expander, in this case, there appears to be nearly 1:1 movement of the molars with the turning of the screw (rough 5.6 mm activation over 4 weeks, and molars expanded around 5.2 mm). If a maxillary expander is borne on TADs only, it seems

that there is little potential for relapse and thus no need for a significant overcorrection. First, because the teeth are not loaded they are not likely to relapse. Second, a skeletal retainer can be used to retain the transversal width over a relatively long period. However, this should be investigated in a larger sample in the future.

## CONCLUSIONS

RME is possible with a prefabricated expander fixed on 2 mini-implants in the anterior palate. This procedure allows a single appointment for insertion of the mini-implants and the expander without the need for an impression. Especially when aligners are going to be used, the use of this mini-implant borne expander seems to be reasonable because the expander can be left in place as a skeletal retainer during the aligner finishing. Studies are now needed to assess if this approach can be replicated in a larger study group and also in older patients with an anticipated higher resistance in the suture.

## REFERENCES

- Kurol J, Berglund L. Longitudinal study and cost-benefit analysis of the effect of early treatment of posterior cross-bites in the primary dentition. *Eur J Orthod* 1992;14:173-9.
- Camacho M, Chang ET, Song SA, Abdullatif J, Zaghi S, Pirelli P, et al. Rapid maxillary expansion for pediatric obstructive sleep apnea: a systematic review and meta-analysis. *Laryngoscope* 2017;127:1712-9.
- Garib DG, Henriques JF, Janson G, de Freitas MR, Fernandes AY. Periodontal effects of rapid maxillary expansion with tooth-tissue-borne and tooth-borne expanders: a computed tomography evaluation. *Am J Orthod Dentofacial Orthop* 2006;129:749-58.
- Schuster G, Borel-Scherf I, Schopf PM. Frequency of and complications in the use of RPE appliances—results of a survey in the Federal State of Hesse, Germany. *J Orofac Orthop* 2005;66:148-61.
- Erverdi N, Okar I, Küçükkeles N, Arbak S. A comparison of two different rapid palatal expansion techniques from the point of root resorption. *Am J Orthod Dentofacial Orthop* 1994;106:47-51.
- Akyalcin S, Alexander SP, Silva RM, English JD. Evaluation of three-dimensional root surface changes and resorption following rapid maxillary expansion: a cone beam computed tomography investigation. *Orthod Craniofac Res* 2015;18(Suppl 1):117-26.
- Wilmes B, Nienkemper M, Drescher D. Application and effectiveness of a mini-implant- and tooth-borne rapid palatal expansion device: the hybrid hyrax. *World J Orthod* 2010;11:323-30.
- Wilmes B, Drescher D. A miniscrew system with interchangeable abutments. *J Clin Orthod* 2008;42:574-80: quiz 595.
- Wilmes B. Fields of application of mini-implants. In: Ludwig B, Baumgaertel S, Bowman J, editors. *Innovative anchorage concepts. Mini-implants in orthodontics*. Berlin: Quintessenz; 2008. p. 91-122.
- Wilmes B. Anwendungsgebiete von Mini-Implantaten. In: Ludwig B, editor. *Mini-Implantate in der Kieferorthopädie—Innovative Verankerungskonzepte*. Berlin: Quintessenz; 2007. p. 89-120.
- Garib DG, Navarro R, Francischone CE, Oltramari PV. Rapid maxillary expansion using palatal implants. *J Clin Orthod* 2008;42:665-71.
- Lee KJ, Park YC, Park JY, Hwang WS. Miniscrew-assisted nonsurgical palatal expansion before orthognathic surgery for a patient with severe mandibular prognathism. *Am J Orthod Dentofacial Orthop* 2010;137:830-9.
- Moon W, Wu KW, MacGinnis M, Sung J, Chu H, Youssef G, et al. The efficacy of maxillary protraction protocols with the micro-implant-assisted rapid palatal expander (MARPE) and the novel N2 mini-implant—a finite element study. *Prog Orthod* 2015;16:16.
- Wilmes B, Ludwig B, Vasudavan S, Nienkemper M, Drescher D. The T-Zone: median vs. paramedian Insertion of palatal Mini-Implants. *J Clin Orthod* 2016;50:543-51.
- Becker K, Unland J, Wilmes B, Tarraf NE, Drescher D. Is there an ideal insertion angle and position for orthodontic mini-implants in the anterior palate? A CBCT study in humans. *Am J Orthod Dentofacial Orthop* 2019;156:345-54.
- Kang S, Lee SJ, Ahn SJ, Heo MS, Kim TW. Bone thickness of the palate for orthodontic mini-implant anchorage in adults. *Am J Orthod Dentofacial Orthop* 2007;131(4 Suppl):S74-81.
- Celenk-Koca T, Erdinc AE, Hazar S, Harris L, English JD, Akyalcin S. Evaluation of miniscrew-supported rapid maxillary expansion in adolescents: a prospective randomized clinical trial. *Angle Orthod* 2018;88:702-9.
- Lin L, Ahn HW, Kim SJ, Moon SC, Kim SH, Nelson G. Tooth-borne vs bone-borne rapid maxillary expanders in late adolescence. *Angle Orthod* 2015;85:253-62.
- Gunyuz Toklu M, Germec-Cakan D, Tozlu M. Periodontal, dentoalveolar, and skeletal effects of tooth-borne and tooth-bone-borne expansion appliances. *Am J Orthod Dentofacial Orthop* 2015;148:97-109.
- Bazargani F, Magnuson A, Ludwig B. Effects on nasal airflow and resistance using two different RME appliances: a randomized controlled trial. *Eur J Orthod* 2018;40:281-4.
- Yildirim M, Akin M. Comparison of root resorption after bone-borne and tooth-borne rapid maxillary expansion evaluated with the use of microtomography. *Am J Orthod Dentofacial Orthop* 2019;155:182-90.
- Feldmann I, Bazargani F. Pain and discomfort during the first week of rapid maxillary expansion (RME) using two different RME appliances: a randomized controlled trial. *Angle Orthod* 2017;87:391-6.
- Papageorgiou SN, Koletsis D, Iliadi A, Peltomaki T, Eliades T. Treatment outcome with orthodontic aligners and fixed appliances: a systematic review with meta-analyses. *Eur J Orthod* 2020;42:331-43.
- Papadimitriou A, Mousoulea S, Gkantidis N, Kloukos D. Clinical effectiveness of Invisalign® orthodontic treatment: a systematic review. *Prog Orthod* 2018;19:37.
- Houle JP, Piedade L, Todescan R Jr, Pinheiro FH. The predictability of transverse changes with Invisalign. *Angle Orthod* 2017;87:19-24.
- Zhou N, Guo J. Efficiency of upper arch expansion with the Invisalign system. *Angle Orthod* 2020;90:23-30.
- Di Leonardo B, Ludwig B, Lisson JA, Contardo L, Mura R, Hourfar J. Insertion torque values and success rates for paramedian insertion of orthodontic mini-implants: a retrospective study. *J Orofac Orthop* 2018;79:109-15.
- Hourfar J, Bister D, Kanavakis G, Lisson JA, Ludwig B. Influence of interradicular and palatal placement of orthodontic mini-implants on the success (survival) rate. *Head Face Med* 2017;13:14.
- Lim HJ, Choi YJ, Evans CA, Hwang HS. Predictors of initial stability of orthodontic miniscrew implants. *Eur J Orthod* 2011;33:528-32.
- Mohammed H, Wafae K, Rizk MZ, Almuzian M, Sosly R, Bearn DR. Role of anatomical sites and correlated risk factors on the survival of orthodontic miniscrew implants: a systematic review and meta-analysis. *Prog Orthod* 2018;19:36.
- Karagkiolidou A, Ludwig B, Pazera P, Gkantidis N, Pandis N, Katsaros C. Survival of palatal miniscrews used for orthodontic appliance anchorage: a retrospective cohort study. *Am J Orthod Dentofacial Orthop* 2013;143:767-72.

32. Ludwig B, Glasl B, Bowman SJ, Wilmes B, Kinzinger GS, Lisson JA. Anatomical guidelines for miniscrew insertion: palatal sites. *J Clin Orthod* 2011;45:433-41: quiz 467.
33. Lagravère MO, Carey J, Heo G, Toogood RW, Major PW. Transverse, vertical, and anteroposterior changes from bone-anchored maxillary expansion vs traditional rapid maxillary expansion: a randomized clinical trial. *Am J Orthod Dentofacial Orthop* 2010;137:304.e301-12: discussion 304-5.
34. Moon HW, Kim MJ, Ahn HW, Kim SJ, Kim SH, Chung KR, et al. Molar inclination and surrounding alveolar bone change relative to the design of bone-borne maxillary expanders: a CBCT study. *Angle Orthod* 2020;90:13-22.
35. Kayalar E, Schauseil M, Kuvat SV, Emekli U, Fıratlı S. Comparison of tooth-borne and hybrid devices in surgically assisted rapid maxillary expansion: a randomized clinical cone-beam computed tomography study. *J Craniomaxillofac Surg* 2016;44:285-93.
36. Ludwig B, Baumgaertel S, Zorkun B, Bonitz L, Glasl B, Wilmes B, et al. Application of a new viscoelastic finite element method model and analysis of miniscrew-supported hybrid hyrax treatment. *Am J Orthod Dentofacial Orthop* 2013;143:426-35.
37. Baccetti T, Franchi L, Cameron CG, McNamara JA Jr. Treatment timing for rapid maxillary expansion. *Angle Orthod* 2001;71:343-50.
38. Carlson C, Sung J, McComb RW, Machado AW, Moon W. Microimplant-assisted rapid palatal expansion appliance to orthopedically correct transverse maxillary deficiency in an adult. *Am J Orthod Dentofacial Orthop* 2016;149:716-28.
39. Becker K, Wilmes B, Grandjean C, Drescher D. Impact of manual control point selection accuracy on automated surface matching of digital dental models. *Clin Oral Investig* 2018;22:801-10.